



2020

Ultraslow Thrombolytic Therapy In Stuck Mechanical Aortic Valve, Case Report, And Review Of The Literature

Follow this and additional works at: <https://www.j-saudi-heart.com/jsha>



Part of the [Cardiology Commons](#)



This work is licensed under a [Creative Commons Attribution-Noncommercial-No Derivative Works 4.0 License](#).

Recommended Citation

Naeim, Hesham Abdo; Amoudi, Osama; Karam, Amjad; Mahmood, Abeer; Albagi, Ahmed; Alharbi, Ibraheem; and Abuelatta, Reda (2020) "Ultraslow Thrombolytic Therapy In Stuck Mechanical Aortic Valve, Case Report, And Review Of The Literature," *Journal of the Saudi Heart Association*: Vol. 32 : Iss. 2 , Article 5.

Available at: <https://doi.org/10.37616/2212-5043.1033>

This Case Report is brought to you for free and open access by Journal of the Saudi Heart Association. It has been accepted for inclusion in Journal of the Saudi Heart Association by an authorized editor of Journal of the Saudi Heart Association.

Ultraslow Thrombolytic Therapy In Stuck Mechanical Aortic Valve, Case Report, And Review Of The Literature

Cover Page Footnote

The authors want to acknowledge Dr. Ibraheem Alharbi and Dr. Refat Alharach for their role during the production of this article.

Ultraslow thrombolytic therapy in stuck mechanical aortic valve, case report, and review of the literature

Hesham Abdo Naeim ^{a,*}, Osama Alamodi ^a, Amjad Karam ^b, Abeer Mahmood ^a, Ahmed Albagi ^a, Ibraheem Alharbi ^a, Reda Abuelatta ^a

^a Madinah Cardiac Center, Saudi Arabia

^b Taiba University, Saudi Arabia

Abstract

Background: Stuck mechanical heart valves had a debate about the management plan. There is debate regarding the type, dose, and rate of administration of various thrombolytic agents. We report a case with successful thrombolysis using an ultraslow regimen.

Case summary: A 43-year-old female with a history of aortic valve (AV) and mitral valve replacement (bi-leaflet metallic valves), and tricuspid valve repair (MINI band) at October 2017. Physical examination showed normal metallic first heart sound and weak metallic second heart sound. Laboratory investigations were normal except low INR, hematocrit, and hemoglobin level (9 gm/L due to iron deficiency anemia). Transthoracic echocardiogram (TTE) and Transoesophageal echocardiogram (TEE) confirmed stuck aortic valve leaflet, with a high mean pressure gradient across prosthetic AV (34 mmHg). The mechanical mitral valve was working well. Fluoroscopy showed stuck one of the AV leaflets in a closed position. The treating physician decided to give her the chance for thrombolytic therapy. This case was treated with ultraslow thrombolytic therapy (Alteplase, 1 mg, every hour) with follow up transthoracic echocardiogram every 24 h to check the pressure gradient on the AV. She was young, asymptomatic, and hemodynamically stable. After 48 h of Alteplase, the stuck leaflet was released. The mean pressure gradient dropped to 16 mmHg.

Discussion: Ultraslow thrombolytic regimen advised to be tried in stuck mechanical valves and hemodynamically stable patients.

Keywords: Stuck, Mechanical valve, Aortic, Thrombolytic, Case report

1. Introduction

Strict adherence to oral anticoagulation is one of the major limitations of prosthetic valves. The rate of prosthetic valve thrombosis (PVT) was estimated to be between 0.03% and 0.13% per patient-year [1]. The mortality rates reported being from 6% to 69% (average 12%) [2,3]. Multiple thrombolytic regimens have been developed to improve the outcome. There is debate regarding the type, dose, and rate of administration of various thrombolytic agents. There is no

clear consensus about the predictors of thrombolytic therapy complications especially major bleeding. Direct comparison of fibrinolysis with surgery is difficult, so, current guidelines depend on expert opinions and non-randomized trials with no class IA recommendations being given. AHA/ACC 2017 guidelines mentioned that slow-infusion fibrinolytic therapy has higher success rates and lower complication rates than prior high-dose regimens and is effective in patients previously thought to require urgent surgical intervention [4]. ESC/EACTS 2017 guidelines

Received 25 January 2020; revised 24 March 2020; accepted 27 March 2020.
Available online 8 May 2020

* Corresponding author at: Madinah Cardiac Center, Madina, Khaled Bin Walid Street, PO 6167, Saudi Arabia.
E-mail address: heshamnieem@yahoo.com (H.A. Naeim).



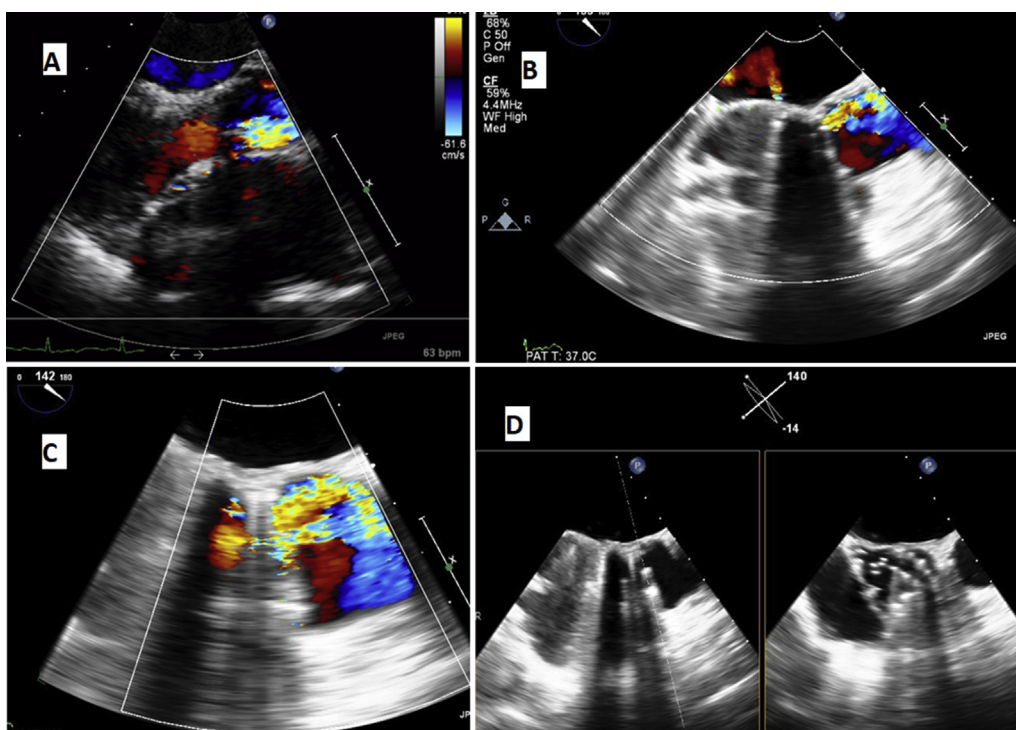


Fig. 1. A: TTE parasternal long-axis view, note the flow acceleration at the lower half of the AV while no flow in the upper half. B: TEE LVOT view at 130 degrees, note the accelerated flow in the upper part of AV. C: TEE modified long axis view showed the color flow only from one half of the AV. D: X-plan at LVOT showed one moving AV leaflet.

mentioned that urgent or emergency valve replacement is recommended for obstructive thrombosis in critically ill patients without serious comorbidity, I C. Fibrinolysis should be considered when surgery is not available or is very high risk, II a C [5]. Society of Heart Valve Disease has recommended fibrinolysis as first-line therapy in the absence of a contraindication [6]. We present a case of successful thrombolysis of stuck aortic valve using the ultraslow infusion of alteplase.

2. Case description

A 43-year-old female patient with a history of rheumatic heart disease causing aortic valve (AV) and mitral valve (MV) stenosis which was treated with AV and MV replacement (bi-leaflet metallic valves), and tricuspid valve repair (MINI band) at October 2017. She had persistent atrial fibrillation. The patient had a history of left leg embolectomy in 2017 and history of old left atrial appendage thrombus. The patient was admitted from the outpatient clinic due to a sub-therapeutic international normalized ratio (INR: 1.48) because the patient was missing her follow up appointments.

Physical examination showed alert and oriented patient, looked well, not dyspneic or tachycardic, vitally stable, pulse was 69 b/min and irregular. Cardiological examination showed normal metallic first heart sound and weak metallic second heart sound. There were ejection systolic murmur grade III/VI and no additional sounds. The chest was clear and there was no lower limb edema.

Laboratory investigations were normal except for low INR, hematocrit, and hemoglobin level (9 gm/L due to iron deficiency anemia). The electrocardiogram showed controlled atrial fibrillation.

On TTE parasternal long-axis view, flow acceleration at the lower half of the AV was seen, while no flow was seen in the upper half (Fig. 1A). On TEE left ventricular outflow tract (LVOT) view showed accelerated flow in the upper part of AV (Fig. 1B), and on modified long axis view the color flow was only from one half of the AV (Fig. 1C). X-plan at LVOT showed one moving AV leaflet (Fig. 1D).

Fluoroscopy confirmed this diagnosis clarifying stuck one of the AV leaflets in a closed position (Fig. 2A). However, fluoroscopy will not be helpful in identifying non-obstructive PVT or differentiating pannus from thrombus [7]. Continuous doppler flow on AV showed the mean PG of 34 mmHg

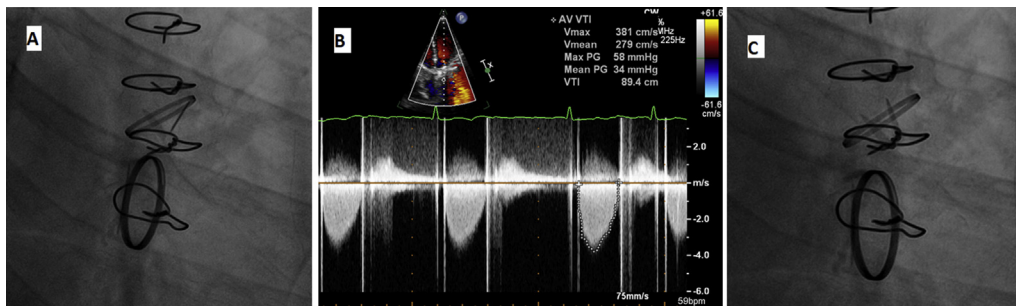


Fig. 2. A: Fluoroscopy showed stuck one of the AV leaflets in a closed position. B: Continuous doppler flow on AV, the mean PG is 34 mmHg. C: After 48 h of Alteplase the stuck leaflet was released.

(Fig. 2B). The heart team meeting opinion divided, some advised open heart surgery for AVR while others advised thrombolytic therapy. The cardiac surgeon was ready to take the patient to the operation room for aortic valve replacement. The treating physician decided to give her the chance for thrombolytic therapy. This case was treated with ultraslow thrombolytic therapy (Alteplase, 1 mg, every one hour) with follow up transthoracic echocardiogram every 24 h to check the pressure gradient on the AV. She was young, asymptomatic, and hemodynamically stable. After 48 h of Alteplase, the stuck leaflet was released (Fig. 2C).

The transthoracic parasternal long-axis view showed the color flow acceleration through both AV leaflets (Fig. 3A). The mean pressure gradient dropped to 16 mmHg. (Fig. 3B).

The patient discharged and follow up TTE after 3 months showed a normally functioning both mechanical valves.

3. Discussion

It is strange for the high flow aortic valve to be stuck while the low flow MV is normal. Although this is infrequent situation, it is reported in many cases including our case. The most common cause of

mechanical valve dysfunction is thrombosis especially in the setting of low INR. In the mechanical AV, it is difficult to visualize the thrombus by echocardiogram but we can expect the presence of thrombus from leaflet stuck in closed or opened position.

Karthikeyan et al. searched EMBASE and MEDLINE up to 2012 and included seven eligible studies with 690 episodes of PVT, 446 treated with surgery, and 244 with fibrinolytic therapy (FT). They concluded that urgent surgery was not superior to fibrinolytic therapy at restoring valve function, but substantially reduced the occurrence of thromboembolic events, major bleeding, and recurrent PVT [8]. However, those results need to be confirmed with randomized controlled trials.

The problem with thrombolytic therapy is the complications mainly the bleeding and thromboembolism. The theory was if we lower the dose of the thrombolytic agent and prolong the duration of infusion, we may decrease the complication rates to be lower than surgical intervention. TROIA trial enrolled 182 patients with PVT and compared 5 different thrombolytic regimens [9]. The endpoints were a thrombolytic success, in-hospital mortality, and nonfatal complication rates. TROIA investigators concluded that Low-dose slow infusion of t-PA repeated as needed without a bolus provides

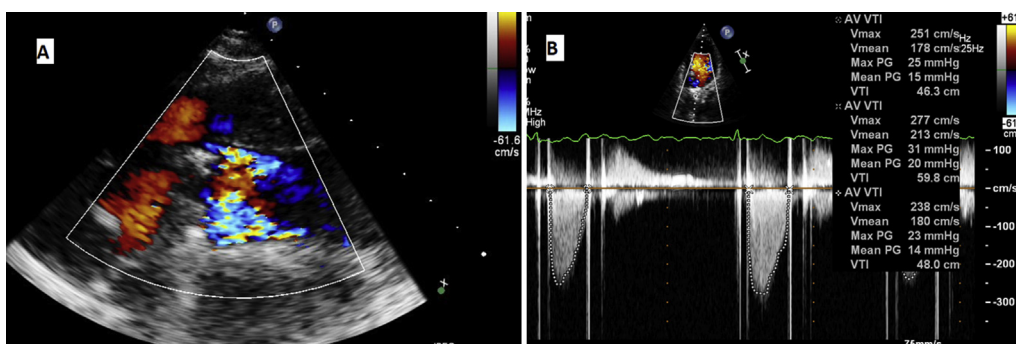


Fig. 3. A: TTE after 2 days showed the color flow from both AV leaflets. B: The mean PG across mechanical AV decreased to 16 mmHg.

effective and safe thrombolysis in patients with prosthetic valve thrombosis [9].

The Ultra-slow PROMETEE trial enrolled 114 patients with PVT. Ultraslow infusion (25 h) of low-dose (25 mg) t-PA, as the FT regimen, was used in all patients. The overall success rate of FT was 90%. The overall complication rate was 6.7% (3.3% nonfatal major, 2.5% minor, and 0.8% death). The predictors of complications were the presence of atrial fibrillation, higher NYHA class, and thrombus area [10]. They concluded that Ultraslow (25 h) infusion of low-dose (25 mg) t-PA without bolus appears to be associated with quite low nonfatal complications and mortality for PVT patients without loss of effectiveness, except for those with NYHA class IV [10]. The PROMETTE investigators hypothesized that further prolongation of the FT regimen could be associated with lower complication rates. Ultraslow dose thrombolytic therapy can be given up to 8 days as soon as the patient is stable. Failure of thrombolysis is considered if the leaflet remained stuck after 8 days. After thrombolysis failure, surgery should be the only option.

This case is consistent with most of those trials. We recommend starting an ultraslow regimen of thrombolysis for stuck mechanical valves in hemodynamically stable patients.

Conclusion: Ultraslow thrombolytic regimen should be tried for stuck mechanical heart valves before surgery in hemodynamically stable patients. Meticulous transthoracic echocardiogram follow up for mechanical valves with low threshold transesophageal echocardiogram for patients with elevated gradient is recommended.

Authors' contribution

Hesham Abdo Naeim, wrote the manuscript.

Osama Alamodi helped in writing the manuscript and language revision.

Amjad Karam collected the literature revision and helped in writing the manuscript.

Ibraheem Alharbi, helped in software and revised the manuscript.

Abeer Mahmood, Helped in collecting echocardiogram figures.

Reda Abuelatta, Revised the manuscript.

Conflicts of Interest

The authors declare that they have no conflicts of interest.

References

- [1] Hammermeister K, Sethi GK, Henderson WG, Grover FL, Oprian C, Rahimtoola SH. Outcomes 15 years after valve replacement with a mechanical versus a bioprosthetic valve: final report of the veterans affairs randomized trial. *J. Am. Coll. Cardiol.* 2000;36:1152–8.
- [2] Karthikeyan G, Senguttuvan NB, Joseph J, et al. Urgent surgery compared with fibrinolytic therapy for the treatment of left-sided prosthetic heart valve thrombosis: a systematic review and metaanalysis of observational studies. *Eur. Heart J.* 2013;34:1557–66.
- [3] Bonou M, Lampropoulos K, Barbetseas J. Prosthetic heart valve obstruction: thrombolysis or surgical treatment? *Eur. Heart J. Acute Cardiovasc. Care* 2012;1:122–7.
- [4] Nishimura RA, Otto CM, Bonow RO, et al. 2017 AHA/ACC Focused Update of the 2014 AHA/ACC guideline for the management of patients with valvular heart disease: a report of the American College of Cardiology/American Heart Association task force on clinical practice guidelines. *Circulation* 2017;135:e1159–95.
- [5] The task force for the management of Valvular Heart Disease of the European Society of Cardiology (ESC), the European Association for Cardio-Thoracic Surgery (EACTS). 2017 ESC/EACTS guidelines for the management of valvular heart disease. *Eur. Heart J.* 2017;38:2739–91.
- [6] Lengyel M, Horstkotte D, Voller H, Mistiaen WP. Recommendations for the management of prosthetic valve thrombosis. *J. Heart Valve Dis.* 2005;14:567–75.
- [7] Raymond Roudaut, Karim Serri, Lafitte Stephane. Thrombosis of prosthetic heart valves: diagnosis and therapeutic considerations *Heart* 2007 Jan;93(1):137–42. <https://doi.org/10.1136/hrt.2005.071183>.
- [8] Karthikeyan G, Senguttuvan NB, Joseph Jo, Devasenapathy N, Bahl KV, Airan B. Urgent surgery compared with fibrinolytic therapy for the treatment of left-sided prosthetic heart valve thrombosis: a systematic review and meta-analysis of observational studies. *Eur. Heart J.* 2013;34:1557–66. <https://doi.org/10.1093/eurheartj/ehs486>.
- [9] Özkan M, Gündüz S, Biteker M, et al. Comparison of different TEE-guided thrombolytic regimens for prosthetic valve thrombosis: the TROIA trial. *JACC Cardiovasc Imag.* 2013;6:206–16.
- [10] Özkan Mehmet, Gündüz Sabahattin, Gürsoy Ozan Mustafa, Karakoyun Süleyman, Ali Astarcioğlu Mehmet, Kalçık Macit, et al. Ultraslow thrombolytic therapy: a novel strategy in the management of PROsthetic MEchanical valve Thrombosis and the prEdictors of outcomE: the Ultra-slow PROMETEE trial. <https://doi.org/10.1016/j.ahj.2015.04.025>; 2015.